

Case Report

Diagnosis of Fetal Kabuki Syndrome By Exome Sequencing Following Non-Specific Ultrasound Findings

Hagit Daum^{1,*}, Simcha Yagel², Mordechai Shohat^{3,4,5}

1. Department of Genetics and Metabolic Diseases, Hadassah-Hebrew University Medical Center, Jerusalem, Israel; E-Mail: dhagit100@gmail.com
2. Department of Obstetrics and gynecology, Hadassah-Hebrew University Medical Center, Jerusalem, Israel; E-Mail: simcha.yagel@gmail.com
3. Bio-informatics department, Cancer center, Sheba Medical center, Israel; E-Mail: Mshohat1@gmail.com
4. Institute of Medical Genetics, Maccabi HMO, Rehovot, Israel
5. Sackler Faculty of Medicine, Tel Aviv University, Tel Aviv, Israel

* **Correspondence:** Hagit Daum; E-Mail: dhagit100@gmail.com

Academic Editor: Joep Geraedts

Special Issue: [Genetic Testing](#)

OBM Genetics

2019, volume 3, issue 2

doi:10.21926/obm.genet.1902077

Received: March 11, 2019

Accepted: April 19, 2019

Published: May 15, 2019

Abstract

Background: Fetal exome sequencing is becoming a crucial modality for genetic investigation whenever fetal malformations are documented in the context of normal chromosomal microarray analysis (CMA). When ultrasound findings are non-specific, the robustness of exome sequencing may be the only way to achieve a molecular diagnosis during pregnancy.

Case: We describe a case of multiple non-specific fetal findings with the eventual diagnosis of fetal Kabuki Syndrome by exome sequencing.

Conclusions: This case stresses the importance of fetal exome sequencing when sonographic fetal abnormalities are visualized, without any specific candidate diagnosis. The multi-organ findings raised the index of suspicion; exome sequencing was performed following a normal



© 2019 by the author. This is an open access article distributed under the conditions of the [Creative Commons by Attribution License](#), which permits unrestricted use, distribution, and reproduction in any medium or format, provided the original work is correctly cited.

CMA. Most Kabuki Syndrome patients have a recognizable facial dysmorphism that generally cannot be observed prenatally.

Teaching Points: 1. Syndromes that are easily characterized postnatally, such as Kabuki, may be very difficult to diagnose prenatally using ultrasound alone. 2. Fetal exome sequencing may reveal the molecular diagnosis when non-specific findings are encountered by sonography.

Keywords

Prenatal diagnosis; chromosomal microarray analysis; exome sequencing; fetal malformations; Kabuki syndrome

1. Introduction

The complexity of prenatal diagnosis stems from our inability to directly examine the patient. Fetal malformations observed by ultrasound often prompt genetic investigation, and couples may be counseled on the basis of ambiguous findings, such as increased nuchal translucency or non-specific fetal malformations. Traditional G-banded chromosome analysis for evaluation of fetal malformations identifies aneuploidy or unbalanced chromosomal rearrangements in up to 18-35% of such cases [1, 2]. Chromosomal microarray analysis (CMA), which enables the diagnosis of microdeletion/duplication syndromes, contributes an additional 2.5-6% of diagnoses, depending on the clinical indications [1]. Fetal exome sequencing may contribute 8.5-10% additional diagnostic yield [3, 4] but even as high as 80% in small cohorts, and thus should be considered when other investigations are negative [5, 6]. The time frame of ongoing pregnancy presents a major challenge. Exome sequencing has the advantages of rapid turnaround of results, increased robustness of variant calling and interpretation, and steadily declining cost, making this option a very attractive modality for genetic testing of the fetus, especially in the context of unclear sonographic findings. Here we present a case of nonspecific fetal sonographic findings that were eventually provided a diagnosis by fetal exome sequencing.

2. Case

A 28 year old pregnant woman was referred for genetic evaluation upon diagnosis of several fetal sonographic findings. She and her husband were healthy, of Ashkenazi Jewish ancestry. They had a healthy offspring and this was their second pregnancy. Pre-gestational screening tests, according to the recommendations regarding their ancestry, were all negative. Using maternal serum markers and nuchal translucency measurement, the integrated risk for Down Syndrome was very low (1:10,000). Second trimester early anomaly scan at 15 weeks demonstrated a slightly smaller than normal left cardiac ventricle, suspected agenesis of the left kidney and right double collecting system. A second early anomaly scan raised suspicion of aortic coarctation and demonstrated a small, echogenic left kidney. Fetal echocardiography demonstrated both a small left ventricle and aortic coarctation. After genetic counseling, amniocentesis was performed. CMA was normal (Gene by Gene's GxG ComprehensiveArray v1.0 BeadChip). The midtrimester anomaly scan at 23 weeks confirmed the above cardiac findings (Figure 1) as well as an aberrant right

subclavian artery. In addition, this scan revealed other fetal findings, including small pelvic kidneys with unilateral renal cyst (Figure 2), low set ears, and fetal biometry consistent with a symmetrically small fetus (i.e. measures >1 standard deviation from the mean parameters for gestational age). Fetal exome sequencing was then recommended and trio-exome was performed by Centogene laboratories. It demonstrated a *de novo* nonsense mutation c.5707C>T; p.Arg1903Ter in *KMT2D*, compatible with Kabuki Syndrome. This variant creates a premature stop codon and was previously described as disease causing by Miyake et al in one patient [7] and in one fetus by Normand et al [8]. It is classified as pathogenic according to ACMG (American college of medical genetics) recommendations. This finding was confirmed by Sanger sequencing. Prognostic information regarding variable expression of Kabuki Syndrome, including risk of intellectual disability and structural anomalies, not all of which can be diagnosed by sonography scanning alone, was a critical aid in the couple's decision to terminate the pregnancy. Termination of pregnancy was performed at 28 weeks after approval of a specific committee according to the state law. Recurrence risk was estimated to be low.

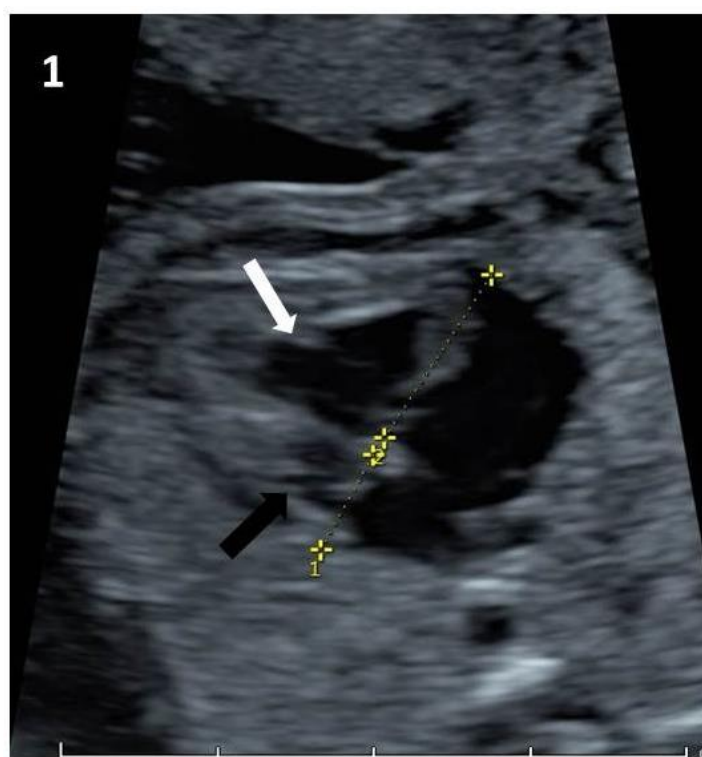


Figure 1 Cardiac left ventricle (black arrow) is very narrow comparing to the right ventricle (white arrow). This may represent aortic coarctation.

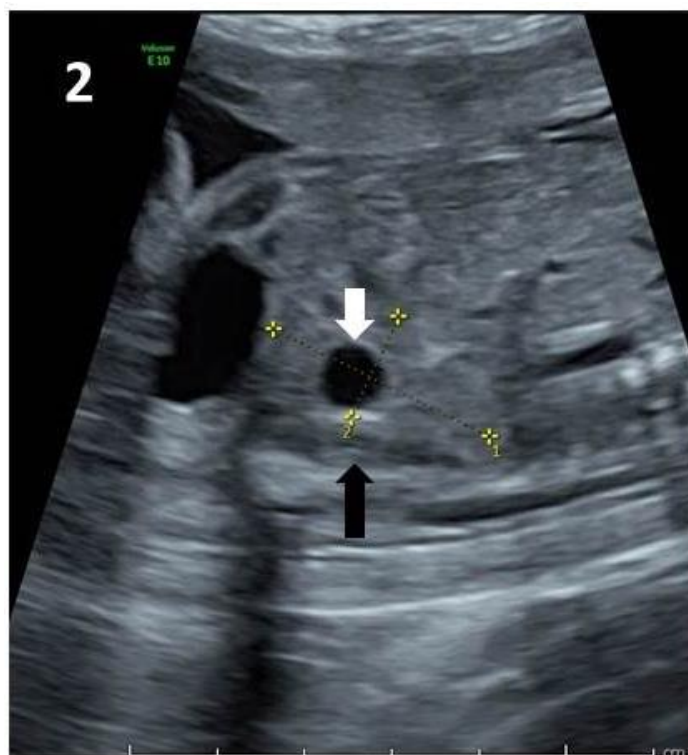

Figure 2 Pelvic kidney (black arrow) with renal cyst (white arrow).

3. Discussion

We report of a case in which a family with a fetus with multiple non-specific fetal abnormalities only received a definitive diagnosis through fetal exome sequencing. Kabuki Syndrome is a rare multi-system disease that is mostly caused by deleterious mutations in the *KMT2D* gene (encoding H3K4 methyltransferase 2D, and in the minority of patients, in *KDM6A*, which encodes H3K27 demethylase) [7]. These proteins are important for the chromatin state and transcription activation that are critical in early vertebrate development. Their reduced expression results in repressed transcription and thus multi-organ abnormalities [9]. Kabuki Syndrome is characterized by variable degrees of intellectual disability, seizures, vision and hearing problems, minor skeletal abnormalities, and growth deficiency. Other findings may include cardiac malformations, genitourinary anomalies, cleft lip and/or palate, gastrointestinal anomalies including anal atresia, ptosis and strabismus, and widely spaced teeth and hypodontia [10]. The most striking feature of the syndrome is the unique facial dysmorphism that includes elongated palpebral fissures with eversion of the lateral third of the lower eyelid, arched and broad eyebrows, short columella with depressed nasal tip and large, prominent, or cupped ears [10]. Persistence of fetal fingertip pads is also a unique, though not pathognomonic, feature of Kabuki Syndrome. This gestalt makes the postnatal clinical diagnosis of Kabuki Syndrome quite clear in most cases, followed by *KMT2D* sequencing or exome sequencing, since only the minority of cases are result of *KDM6A* mutations [11]. Even in cases of clinical features of Kabuki Syndrome, some differential diagnosis may be considered, especially CHARGE Syndrome, but there may be other multi-organ candidate syndromes. Naturally, most of the unique features of Kabuki Syndrome cannot be visualized prenatally. This case highlights the importance of fetal exome sequencing when fetal abnormalities are visualized but do not suggest a specific candidate diagnosis. Otherwise, when

cardiac malformations are observed, next generation sequencing panel may be advised, as described by Hu et al [12]. They diagnosed two fetuses with Kabuki Syndrome by targeted 77-gene panel following the observation of cardiac and renal malformations in these fetuses. A post-mortem genetic analysis is another way to approach fetal malformations as described by Quinlan-Jones et al [13]. When malformations are severe, the couple might opt for termination of pregnancy followed by genetic investigation, assuming grave prognosis anyway or even health conditions that are non-compatible with life. They describe a cohort of 27 fetuses that were terminated following a severe sonographic phenotype. Two of which (one with complex heart malformation and cleft palate; the other with Hydrops fetalis, cleft palate, micrognathia and dysplastic kidneys) had a post-mortem diagnosis of Kabuki Syndrome by exome trio.

In our case, some of the findings would not be termed fetal malformations (pelvic kidneys and mild growth restriction) but their association with multi-organ findings raised the index of suspicion. 3D sonography may allow, in the future, identification of the characteristic fetal facial dysmorphism of Kabuki Syndrome, as was described in some cases of Cornelia de Lange Syndrome and others [14, 15].

Regarding the specific variant found in the fetus described, its pathogenicity was consolidated by observing how it creates a premature stop codon in a gene with loss of function intolerance ($pLI=1$). It was described before as disease causing [7, 8] and is not described in healthy population cohorts like ExAC.

Of note, there are some limitations of whole exome sequencing in the prenatal setting. They include the possibility of finding variants of uncertain clinical significance which pose stress without a clear diagnosis. Another issue is the potential for clinically significant secondary findings like late onset diseases. All of these issues emphasize the importance of skilled genetic counseling prior to undergoing prenatal exome sequencing.

Acknowledgments

The authors thank Mrs. Sara Cohen for the language editing and also to the support of the Adler Chair for Pediatric Cardiac Research, Sackler School of Medicine, Tel-Aviv.

Author Contributions

These authors contributed equally to this work.


Competing Interests

The authors have declared that no competing interests exist.

References

1. Wapner RJ, Martin CL, Levy B, Ballif BC, Eng CM, Zachary JM, et al. Chromosomal microarray versus karyotyping for prenatal diagnosis. *N Engl J Med*. 2012; 367: 2175-2184.
2. Callaway JL, Shaffer LG, Chitty LS, Rosenfeld JA, Crolla JA. The clinical utility of microarray technologies applied to prenatal cytogenetics in the presence of a normal conventional karyotype: a review of the literature. *Prenat Diagn*. 2013; 33: 1119-1123.

3. Lord J, McMullan DJ, Eberhardt RY, Rinck G, Hamilton SJ, Quinlan-Jones E, et al. Prenatal exome sequencing analysis in fetal structural anomalies detected by ultrasonography (PAGE): a cohort study. *Lancet*. 2019; 393: 747-757.
4. Petrovski S, Aggarwal V, Giordano JL, Stosic M, Wou K, Bier L, et al. Whole-exome sequencing in the evaluation of fetal structural anomalies: a prospective cohort study. *Lancet*. 2019; 393: 758-767.
5. Best S, Wou K, Vora N, Van der Veyver IB, Wapner R, Chitty LS. Promises, pitfalls and practicalities of prenatal whole exome sequencing. *Prenat Diagn*. 2018; 38: 10-19.
6. Daum H, Meiner V, Elpeleg O, Harel T. Fetal exome sequencing: yield and limitations in a tertiary referral center. *Ultrasound Obstet Gynecol*. 2019; 53: 80-86.
7. Miyake N, Koshimizu E, Okamoto N, Mizuno S, Ogata T, Nagai T, et al. MLL2 and KDM6A mutations in patients with Kabuki syndrome. *Am J Med Genet A*. 2013; 161a: 2234-2243.
8. Normand EA, Braxton A, Nassef S, Ward PA, Vetrini F, He W, et al. Clinical exome sequencing for fetuses with ultrasound abnormalities and a suspected Mendelian disorder. *Genome Med* 2018; 10: 74.
9. Van Laarhoven PM, Neitzel LR, Quintana AM, Geiger EA, Zackai EH, Clouthier DE, et al. Kabuki syndrome genes KMT2D and KDM6A: functional analyses demonstrate critical roles in craniofacial, heart and brain development. *Hum Mol Genet*. 2015; 24: 4443-4453.
10. Bogershausen N, Wollnik B. Unmasking Kabuki syndrome. *Clin Genet*. 2013; 83: 201-211.
11. Cheon CK, Sohn YB, Ko JM, Lee YJ, Song JS, Moon JW, et al. Identification of KMT2D and KDM6A mutations by exome sequencing in Korean patients with Kabuki syndrome. *J Hum Genet*. 2014; 59: 321-325.
12. Hu P, Qiao F, Wang Y, Meng L, Ji X, Luo C, et al. Clinical application of targeted next-generation sequencing in fetuses with congenital heart defect. *Ultrasound Obstet Gynecol*. 2018; 52: 205-211.
13. Quinlan-Jones E, Lord J, Williams D, Hamilton S, Marton T, Eberhardt RY, et al. Molecular autopsy by trio exome sequencing (ES) and postmortem examination in fetuses and neonates with prenatally identified structural anomalies. *Genet Med*. 2019; 21: 1065-1073.
14. Spaggiari E, Vuillard E, Khung-Savatovsky S, Muller F, Oury JF, Delezoide AL, et al. Ultrasound detection of eyelashes: a clue for prenatal diagnosis of Cornelia de Lange syndrome. *Ultrasound Obstet Gynecol*. 2013; 41: 341-342.
15. Clark DM, Sherer I, Deardorff MA, Byrne JL, Loomes KM, Nowaczyk MJ, et al. Identification of a prenatal profile of Cornelia de Lange syndrome (CdLS): a review of 53 CdLS pregnancies. *Am J Med Genet A*. 2012; 158a: 1848-1856.



Enjoy *OBM Genetics* by:

1. [Submitting a manuscript](#)
2. [Joining in volunteer reviewer bank](#)
3. [Joining Editorial Board](#)
4. [Guest editing a special issue](#)

For more details, please visit:

<http://www.lidsen.com/journals/genetics>